Thalamic Tremor Following Focused Ultrasound Thalamotomy for Essential Tremor

Thomas Osterholt[1], Alessandro Fois[2], Patrick McGurrin[1], Traian Popa[1], Felipe Vial[1], Silvina Horovitz[1], Mark Hallett[1], Dietrich Haubenberger[1]
[1]National Institute of Neurological Disorders and Stroke, Division of Intramural Research [2]The University of Sydney, Westmead Clinical School

Introduction

- Magnetic Resonance Guided Focused Ultrasound Thalamotomy, (MRgFUS) was approved by the FDA for the treatment of medically refractory Essential Tremor (ET) in 2016 [1]
- Tremor has been reported as a potential sequela after thalamic lesions, typically following stroke, tumors, or other tissue disruptions
- To our knowledge, no cases of dystonia and/or tremor have been described following MRgFUS thalamotomies

Report of a Case

- A 70-year-old right-handed male ET patient developed dystonic posturing with a novel low-frequency tremor of the right hand >1 year after MRgFUS of the left thalamus
- The diagnosis ET has been confirmed in our clinic, where the patient is being followed for >10 years. Other than bilateral action- and postural tremor, with amplitudes right>left, there were no other abnormal movements in his neurological exam, in particular no signs of dystonia or parkinsonism.
- MRgFUS was performed in 2016 for treatment of refractory right hand ET
- Here we aimed to examine the neuroanatomical and neurophysiological correlates of the newly developed movement abnormality, and compare to pre-intervention findings.

Methods

- Tremor electrophysiology was recorded using bilateral
  - Electromyography (EMG) of the extensor digitorum communis (EDC) and flexor carpi ulnaris muscles (FCU).
  - Accelerometry, recorded from sensors on the dorsum of the hand.
  - Accelerometry was recorded during posture of both hands, as well as after the addition of 1 lbs weight to each hand to separate the peripheral from the central tremor component
- 3T and 7T MRI scan were performed for lesion anatomical localization.
- Electrophysiological data were analyzed using in-house developed MATLAB scripts
- MRI data were analyzed with AFNI software suite

2009 – pre MRgFUS

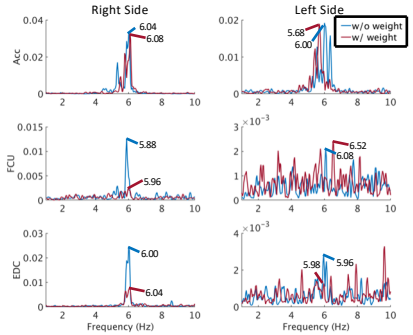

Figure 1. Upper limb tremor study pre-MRgFUS in 2009 demonstrating an apprx. 6 Hz bilateral centrally generated postural tremor

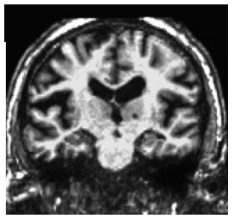

Figure 4. T1 weighted image. Lesion is observed in the left thalamus (Talairach coordinates 14,18,3). Lesion volume was estimate to be 26mm³ it may be smaller due to partial volume loss from imaging resolution.

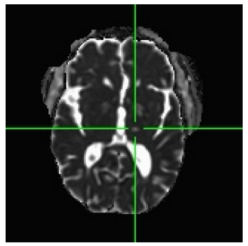

Figure 5. Mapping of the lesion and thalamic nuclei using the Talairach coordinates

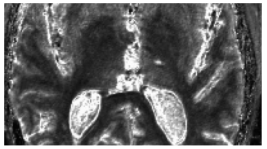

Figure 6. T1 weighted mp2rage sequence 0.70 mm isometric showing fluid filled lesion

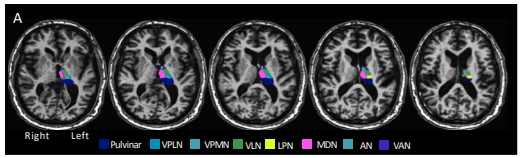

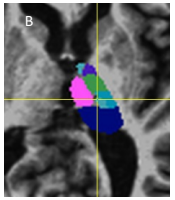

Figure 8. A) Thalamic nuclei from a standardized atlas were registered to subject space. Images show their overlay on T1 weighted images. B) lesion is at the edge of four nuclei, the motor and sensory nuclei (VPLN and VPMN), sensory mdn and in proximity to VL

VPLN – Ventral Posterior Lateral Nuclei, VPMN – Ventral Posterior Medial Nuclei, VLN – Ventral Lateral Nuclei, LPN – Lateral Posterior Nuclei, MDN – Medial Dorsal Nuclei, AN – Anterior Nuclei, VAN – Ventral Anterior Nuclei

2018 – 2 years post MRgFUS

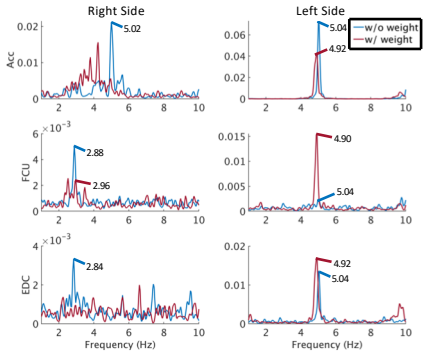

Figure 2. Upper limb tremor study post MRgFUS showing a 2.8 Hz tremor EMG signal with 5Hz frequency on the ACC resulting from volume conduction.

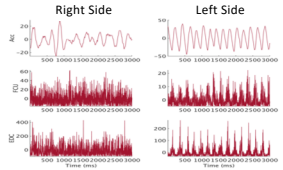

Figure 3. Raw ACC and rectified EMG recordings with 1 lb. weight attached to hands during posture



Figure 7. Dystonic posturing seen post MRgFUS

- Patient reported good response to MRgFUS of his right hand Essential Tremor
- Post-intervention, the patient reported of a self-limiting hypesthesia peri-orally right
- During posture of both hand, the right hand exhibited a tonic finger and hand posture with a flexion and supination movement, as well as a low-amplitude, low-frequency tremor.
- The left hand continued to exhibit a rhythmical, moderate-amplitude postural tremor without any dystonic posturing
- The right hand showed dystonic posturing during walking. No other body-part showed dystonia.

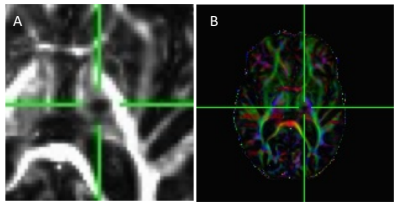

Figure 9.
A)Fractional Anisotropy map. Lesion is fully located within the thalamus.
B) DEC map show the absence of intra-thalamic fibers when comparing left to right. This could be partially due to signal loss. However, given that the lesion is at the edge of the nuclei (l) the intrathalamic fiber may well be affected.

Discussion

- Localization of the lesion demonstrated .... between the VPLN and the VPMN
- Lesions to the VPLN and the VPLM nuclei have been shown to cause tremor and dystonia[2-3]
- The symptoms following MRgFUS may result from plastic changes or maladaptive rearrangement in the thalamus
- Lesions to these areas are understood to project to sensory cortices and process somatosensory information
- More analysis is needed to explore changes in the thalamus post MRgFUS and the symptoms that result

References

1. Elias, W.J., et al., *A Randomized Trial of Focused Ultrasound Thalamotomy for Essential Tremor.* New England Journal of Medicine, 2016. **375**(8): p. 730-739.
2. Miwa, H., et al., *Thalamic tremor: case reports and implications of the tremor-generating mechanism.* Neurology, 1996. **46**(1): p. 75-9.
3. Alvarez, M., et al., *Dystonia and tremor secondary to thalamic infarction successfully treated with thalamotomy of the ventralis intermedius nucleus.* Mov Disord, 2014. **29**(9): p. 1188-90.